

Haplosporidian-like Parasite of Shrimp

I. *Causative Agent and Disease*

Haplosporidian protozoa are within the phylum Haplosporidia, class Haplosporea within the order Haplosporida in the family Haplosporidiidae. Reports of haplosporidians in crustaceans are few and, although they have potential as serious pathogens, their prevalences have been low and distributions rare. An unidentified haplosporidian-like protozoan, previously described as dinoflagellate-like, occurs in spot and pink shrimp where unconfirmed prevalences of 10-50% have been reported. However, documented prevalences have been less than 1% but parasitized prawns did not survive in captivity. Uninucleate stages of the parasite replace hemocytes in the hemal sinuses and multinucleated plasmodial forms occur in tissues causing systemic disease.

II. *Host Species*

This haplosporidian-like parasite has been reported in spot and pink shrimp from the Strait of Georgia in British Columbia, Canada and from Yakutat and Prince William Sound in Alaska.

III. *Clinical Signs*

Parasitized shrimp are lethargic, have an unusual red color with chalky white musculature and characteristic cloudy or milky hemolymph containing myriad numbers of the parasite.

IV. *Transmission*

The mode of transmission is unknown.

V. *Diagnosis*

Wet mounts and stained smears of tissue exudate and hemolymph demonstrate a circular non-motile protozoan

of about 14-20 μm in diameter with a single central nucleus having a distinct outline and no dinokaryotic figures. This nuclear profile distinguishes the parasite from the *Hematodinium* dinoflagellate in Tanner crabs (discussed elsewhere). Histological examination demonstrates the uninucleate form observed systematically within the hemal sinuses and a larger multinucleated plasmodial form within the tissues. Transmission electron microscopy of nuclear detail further demonstrates less condensed nuclear chromatin that does not cause irregular bulging of the well-defined nuclear envelope. These features produce a distinct nuclear profile. Various other ultrastructural features distinguish this parasite from the Tanner crab *Hematodinium* sp.

VI. *Prognosis for Host*

This haplosporidian-like protozoan causes mortality in parasitized shrimp by displacement of hemocytes and normal organ tissues. However, the actual population prevalence may be quite low with insignificant mortality.

VII. *Human Health Significance*

There are no apparent zoonotic human health concerns with the presence of this haplosporidian-like parasite in shrimp. However, the meats of parasitized shrimp may be unsuitable in texture for human consumption.

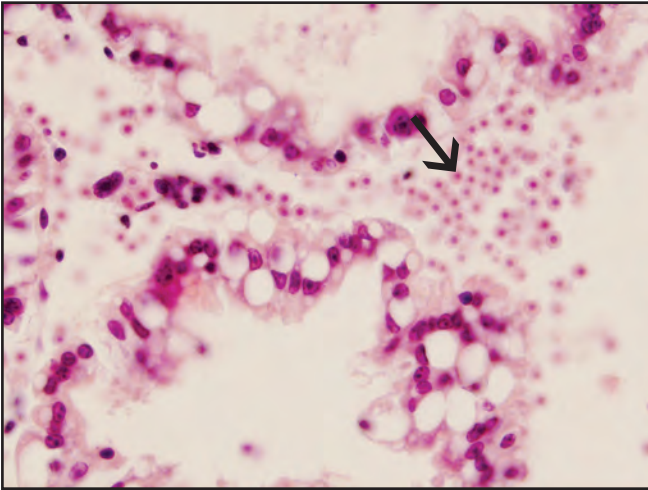


Red "cooked" appearance of spot shrimp parasitized by a haplosporidian-like protozoan

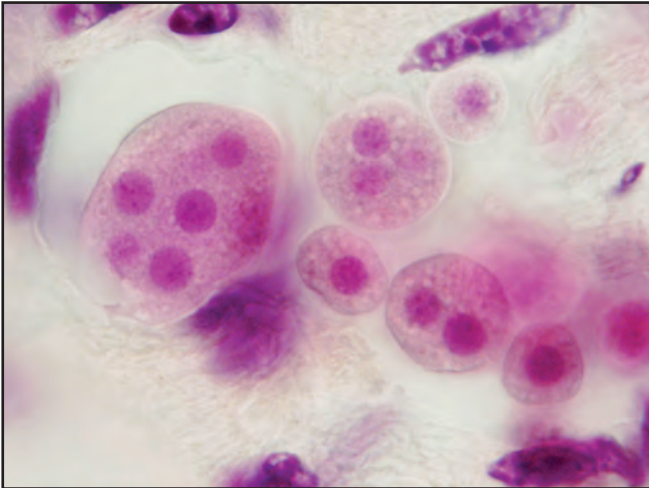


Smear of mucinous milky tissue exudate containing myriad numbers of organisms

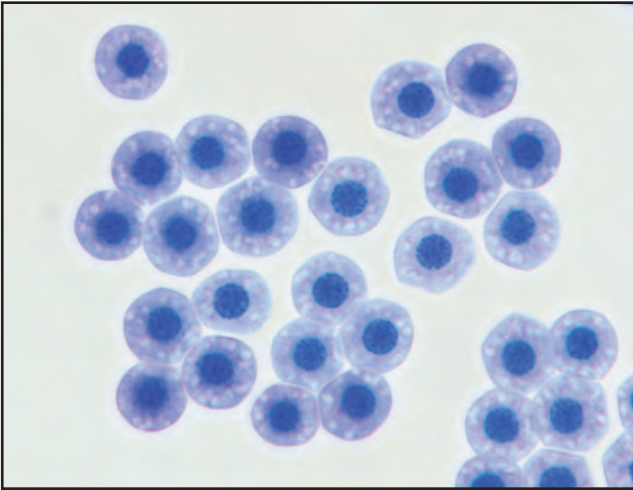
Haplosporidian-like Parasite of Shrimp



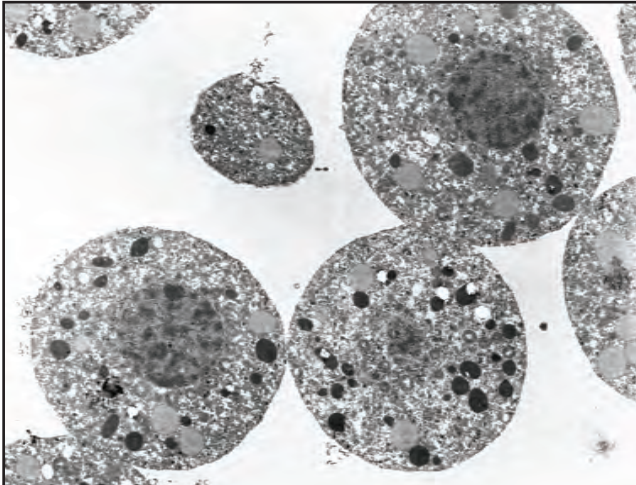
Histological section of a haplosporidian-like parasite (arrow) in the hepatopancreas of spot shrimp



A higher magnification of multinucleated plasmodial forms in histological section



A stained smear of fixed uninucleate forms of the parasite



Ultrastructural detail of the parasite showing less condensed nuclear chromatin and a well defined nuclear profile