

Pacific Oyster Nocardiosis

I. Causative Agent and Disease

Pacific oyster nocardiosis (PON), previously known as “focal necrosis” and “fatal inflammatory bacteremia” (FIB) is caused by an actinomycete bacterium *Nocardia crassostreae* that is Gram-positive or Gram variable, acid fast, PAS positive and catalase positive. The bacterium contributes to “summer mortality” of 2 year and older oysters in shallow, warm eutrophic embayments during August through November when seawater temperature is 20°C or greater. Infection produces small round yellow, green or brown vesicles of bacteria and granulomas 2 mm to 1 cm in diameter throughout oyster tissues resulting in significant mortality.

II. Host Species

This disease is reported to be restricted to Pacific oysters, although a similar disease has been observed in European flat oysters cultivated near areas of infected Pacific oysters. PON has been reported in Pacific oysters from California, Washington, British Columbia, Japan and most recently from the Netherlands. In Alaska, infection by this organism was detected in only two juvenile animals imported from the state of Washington but had been reared in Alaskan waters. Therefore, it is unclear whether the disease can spontaneously occur in the colder seawater temperatures typical of Alaskan summers.

III. Clinical Signs

Clinical signs of PON include moderate to high mortality of young adult oysters that are undergoing physiological stress from rapid gonadal development with presenting lesions of small, round, yellow, green or brown vesicles of bacteria and granulomas in the tissues.

IV. Transmission

The bacterium is considered to be an opportunistic pathogen that is widespread in the marine environment. Transmission is likely horizontal and facilitated by other physical environmental stressors.

V. Diagnosis

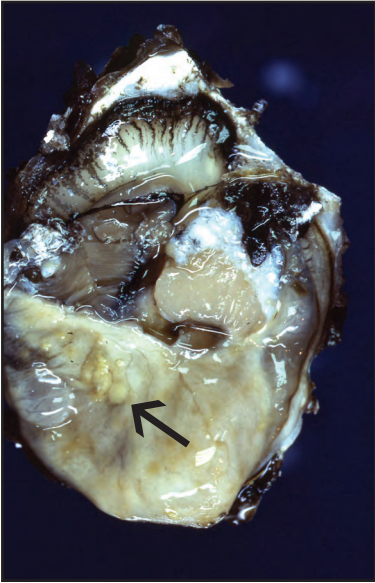
Histological examination of typical lesions in infected oyster tissues indicate Gram-positive or Gram-variable, acid fast foci of bacteria within surface vesicles and in granulomas eliciting a marked host inflammatory response. Confirmation is by fluorescent antibody staining and by transmission electron microscopy showing typical actinomycete morphology. Culture of the organism is possible on several medias for fastidious organisms but is not a routine procedure because the appearance of colony growth may take from 3 weeks to 3 months.

VI. Prognosis for Host

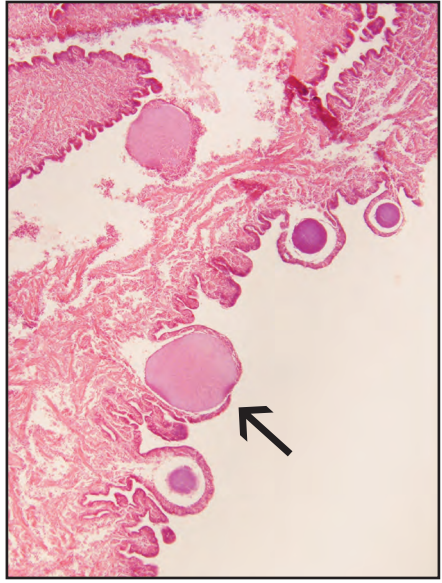
Mortality of infected oysters may be significant but has not been accurately determined in the field. However, experimental injection of the organism has produced 47-50% cumulative mortality of oysters within 30 days. Management techniques have not been investigated but culturing oysters in off-bottom gear and avoidance of shallow warm embayments in the summer may reduce the prevalence and severity of the disease.

VII. Human Health Significance

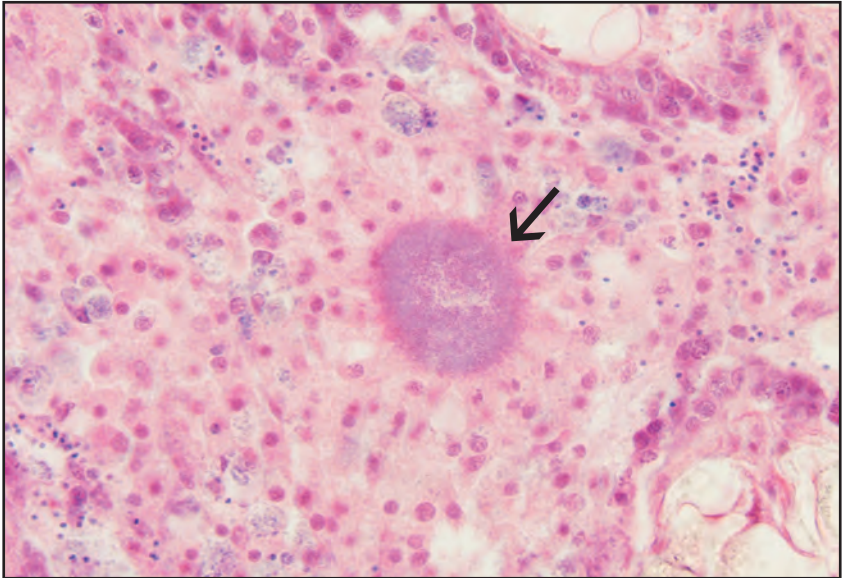Aside from aesthetically displeasing, there are no known zoonotic human health concerns with *Nocardia* infection of Pacific oysters.



Yellow vesicles (arrow) of nocardiosis in the mantle tissues of a Pacific oyster (Photo: R. Elston, AquaTechnics, WA)



Histological section of vesicles containing bacteria (arrow) in infected mantle tissue



Typical subsurface radiating granuloma (arrow) containing central *Nocardia* organisms surrounded by host inflammatory cells, histological section